



**PATIENT**

Willy Kohn

**SPECIES**

Canine

**BREED**

Havanese

**SEX**

MN

**AGE**

8½ years

**WEIGHT**

14 #

**INTERPRETED BY**

Remo Lobetti, BVSc,  
MMedVet (Med),  
PhD, Dipl. ECVIM

**IMAGING  
PERFORMED BY**

Lara Wiseman, DVM

**HOSPITAL NAME**

Calusa Veterinary  
Center

**REFERRING VET**

**INVOICE**

302613

**DATE**

10/25/21

**PRESENTING CLINICAL SIGNS**

History: Acute onset vomiting and diarrhea.

Physical Examination: N/A.

Urinalysis: N/A.

CBC: Normal.

Serum Biochemistry: Normal, including cPL.

Radiographic Findings: N/A.

**ULTRASONOGRAPHIC EXAMINATION OF THE ABDOMEN**

**Urinary System**

Full urinary bladder with a normal thickness and appearance of the wall. Normal anechoic urine with no sediment or uroliths evident.

Normal trigone area, proximal urethra (0.28 cm) and iliac blood vessels.

Normal iliac lymph nodes. Ureters not visualized.

Normal renal size (left 4.3 cm, right 4.7 cm) with increased echogenic appearance, loss of cortico-medullary differentiation, and normal capsule and pelvis.

**Reproductive System**

Small anechoic prostate (0.6 cm).

**Adrenal Glands**

Normal shape, echogenic appearance, size, and position. Left 0.48 cm, right 0.43 cm.

**Spleen**

Normal size (1.1 cm) and echogenic appearance. Smooth homogenous parenchyma, smooth curvi-linear capsule, and normal vasculature. No evidence of inflammatory, neoplastic, infarction, or infiltrative changes noted.

**Liver**

Normal size, echogenic appearance, and portal markings. No nodules or masses evident. Small gall bladder containing normal anechoic bile. Normal appearance and thickness of the gall bladder wall. Normal bile duct (0.18 cm).



**PATIENT**

Willy Kohn

**SPECIES**

Canine

**BREED**

Havanese

**SEX**

MN

**AGE**

8½ years

**WEIGHT**

14 #

**INTERPRETED BY**

Remo Lobetti, BVSc,  
MMedVet (Med),  
PhD, Dipl. ECVIM

**IMAGING PERFORMED BY**

Lara Wiseman, DVM

**HOSPITAL NAME**

Calusa Veterinary  
Center

**REFERRING VET**

**INVOICE**

302613

**DATE**

10/25/21

***Gastrointestinal***

Normal appearance of the gastro-esophageal junction, stomach, pylorus, duodenum, small intestine, ileo-cecal junction, and colon with no loss of layering and normal wall thickness (stomach 0.35 cm, duodenum 0.39 cm, jejunum 0.38 cm) and peristalsis, and no distension of the lumen. Fluid within the cecum. Fluid/fecal material within the colon.

***Pancreas***

Normal size (right 1 cm) and echogenic appearance. Regular capsule. Normal echogenic appearance of the mesentery and fat surrounding the pancreas.

***Free Abdomen***

Mesenteric lymphadenomegaly (1.2 x 0.7 cm) with a normal shape and echogenic appearance.

No ascites.

**ULTRASONOGRAPHIC FINDINGS**

Primary findings:

- Mesenteric lymphadenomegaly.

Secondary findings:

- Age-related renal changes.

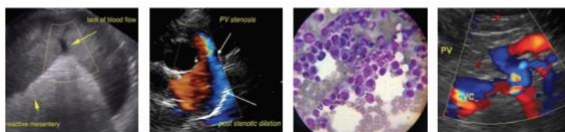
**INTERPRETATION OF THE FINDINGS & FURTHER RECOMMENDATIONS**

The most likely etiology for the lymphadenomegaly would be reactive secondary to the acute enteritis with lymphadenitis and infiltrative neoplasia, differential diagnoses.

The most likely etiology for the presenting clinical signs would be acute gastro-enteritis - dietary indiscretion, toxins, viral, bacterial, protozoal, helminths.

Further assessment would be urine and fecal analyses, and if there is not a satisfactory improvement then FNA cytology of the lymph nodes and endoscopy of both the upper and lower GI tract with biopsies.

Symptomatic therapy would be fluid therapy as needed, intestinal diet, anti-emetics, and intestinal protectants/adsorbents.



**PATIENT**

Willy Kohn

**SPECIES**

Canine

**BREED**

Havanese

**SEX**

MN

**AGE**

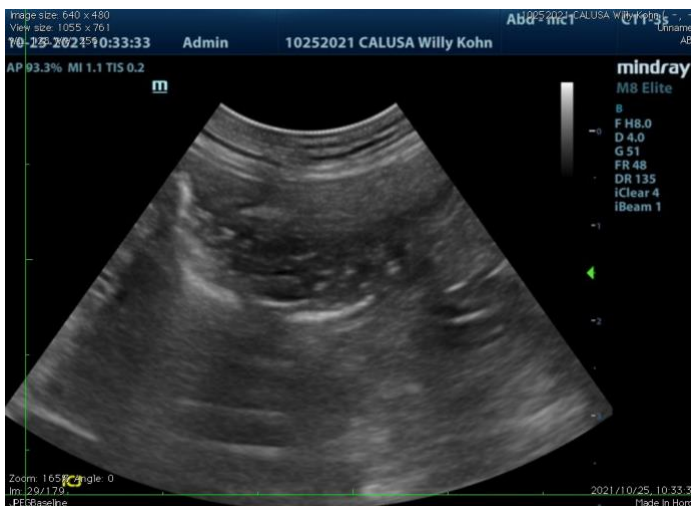8½ years

**WEIGHT**

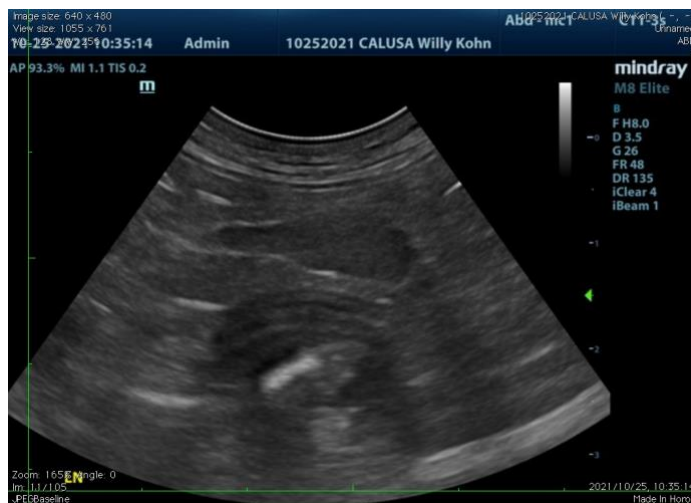14 #

**IMAGES**

**Cecum**



**Mesenteric lymph node**



The information and recommendations provided are based on the images presented by the referring veterinarian. No evaluation can be communicated regarding pathology that was not visible in the image/video clips provided.

Thank you for this referral. If the clinical or image interpretation does not parallel your findings or if I can be of any further assistance please contact me.

**Remo Lobetti, BVSc, MMedVet (Med), PhD, Dipl. ECVIM (Internal Medicine)**  
rlobetti@mweb.co.za

**INTERPRETED BY**

Remo Lobetti, BVSc,  
MMedVet (Med),  
PhD, Dipl. ECVIM

**IMAGING PERFORMED BY**

Lara Wiseman, DVM

**HOSPITAL NAME**

Calusa Veterinary  
Center

**REFERRING VET**

**INVOICE**

302613

**DATE**

10/25/21